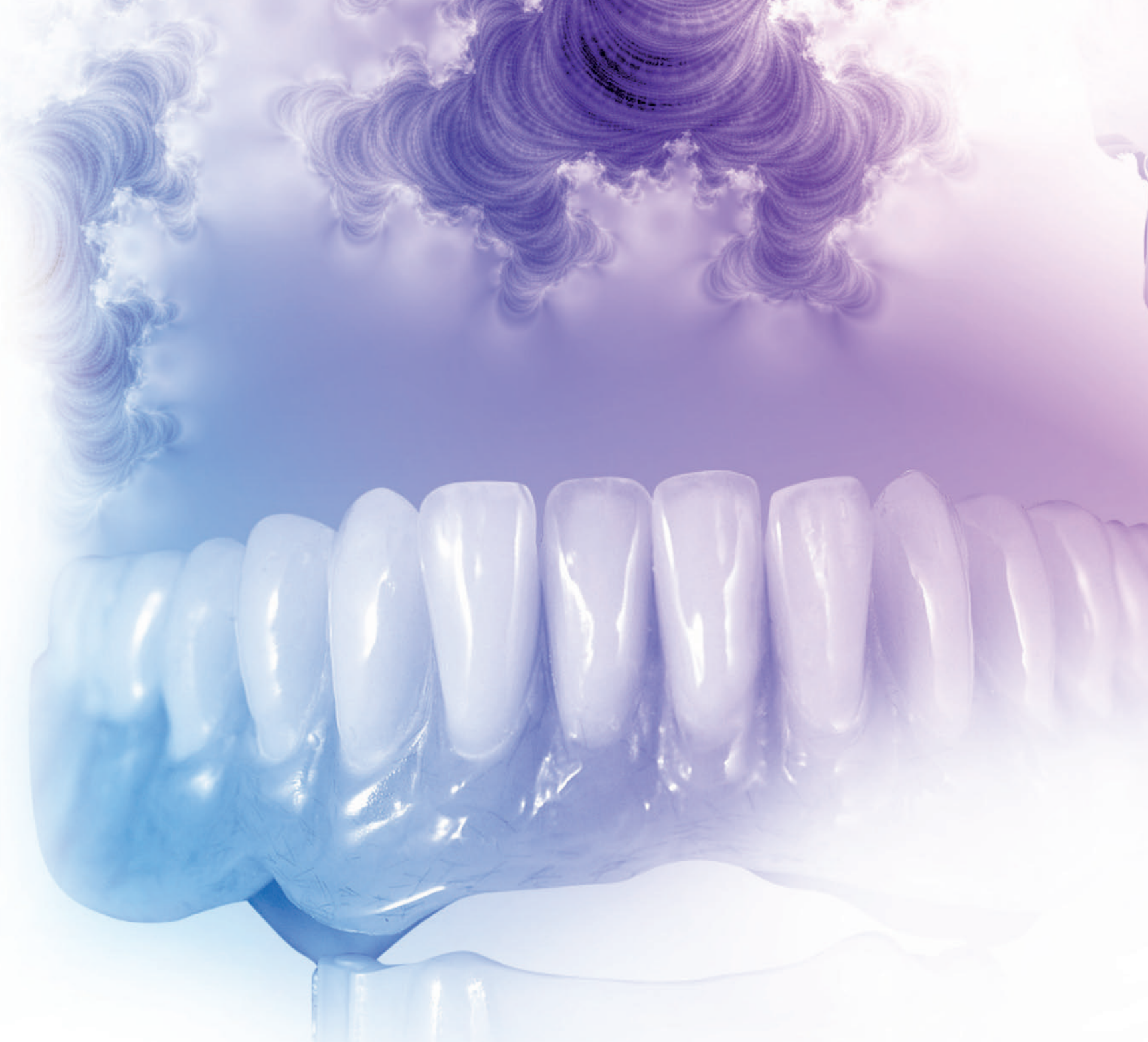



**About the Author**



**Richard B. Winter, D.D.S.M.A.G.D.F.A.D.I.F.I.C.O.I.**, received his dental degree from the University of Minnesota School of Dentistry in 1988.

He received his Mastership in the Academy of General Dentistry (AGD) in 2007 and is currently on the Board of Directors for the Wisconsin AGD. Fellow in the Academy of Dentistry International.



# Upgradeable Dentistry- Part I

Richard Winter D.D.S.M.A.G.D.F.A.D.I

## Introduction

A familiar remark to a dentist is, “Gee doc, I would love to do what you have suggested- if I just had the money.” Well, certainly dentistry is an investment that can be multi-faceted. Patient’s issues are financial as well as value-based. Often dentists are asked to plan treatment options as if the patient was a member of their own family. Certainly, our values are to always choose the best for our patients, but what constitutes “best” must also take into account what is the right thing to do for our patients, given their life circumstances at the time of treatment.

Dr. Paul Homoly discusses doing a fitness check on your patient in his book, “Making it Easy for Patients to Say, “Yes”.<sup>1</sup> He acknowledges that all patients want the best dental care, but they may not be able to afford it at that specific time in their life. How can we help them in an appropriate way without alienating them? Can we demonstrate that we are their advocates on their journeys toward being happy again with their oral condition?

## Defining Upgradeable Dentistry

I discuss “upgradeable dentistry” with all of my patients so they understand that they are on a path toward ideal

dentistry. This is a simple concept that involves understanding that dentistry is a dynamic process, not a static event. This involves helping the patients understand that they are on a path towards ideal dentistry. I inform them that I will be their advocate on their journey and that they will never “lose face” by choosing a particular treatment. They are told that they will always have the opportunity to continually “upgrade” as it is appropriate to their situation.

For example, those dentures from 35 years ago were meant to last 5 years; the 30 years in between have led to severe bone loss, wrinkles, facial changes, loss of vertical dimension, decreased chewing efficiency, poor nutrition-all because the patient didn’t know any differently. Failing restorations can be replaced with a myriad of new restorative materials. The improvement in lost tooth morphology, the establishment of proper contact points and occlusal rehabilitation are all facets of upgrading that tooth. However, a new restoration, of and by itself, isn’t necessarily an “upgrade” unless it addresses the person’s long-term needs. Did we take care of the plunger cusp that led to cuspal ablation and a fracture? Did we equilibrate the super-erupted tooth so our new restoration will be consistent with the occlusal plane parameters (Curve of Spee and Curve of Wilson) of the adjacent teeth?

So “upgradeable dentistry” is a concept that applies to the sequential improvement of a person’s dental condition from the odontoblastic level to the full-smile view. We must always check to make sure that we are providing rehabilitative dentistry as opposed to conformational dentistry. This 4-part article series will provide examples and discussion for those who are not familiar with this patient-centered philosophy of upgradeable patient care.

### The Journey Begins: Standard Dentures or Deluxe Turbyfills?

In figures 1 and 2 we can visualize “upgraded dentures”. These Turbyfill dentures were made with mucostatic impression techniques, and teeth were set chairside for customized aesthetics and phonetics. (Dr. Jack Turbyfill teaches concepts for denture fabrication that he learned from his mentor, Dr. Earl Pound.) Dentures with porcelain teeth, lingualized occlusion, tinted bases and silicone soft denture liners (Molloplast B, Buffalo) are a “deluxe” service that we offer in our office.<sup>2-5</sup> The art of complete dentures carries over into all facets of oral rehabilitation.

To some dentists, the ideal of cosmetic dentistry is to emulate and accomplish artistic form with veneers, inlays, onlays and crowns. However, to quote one of my mentors, Dr. Harold Shavell, “Just because it’s white and bright doesn’t make it right, you have to consider the bite!” He was alluding to the fact that we must not limit our view of the treatment outcome to aesthetics alone, but must strive to improve on the macerated occlusal form with an eye toward function and form. Dentists wear many hats. They view the stomatognathic system in its entirety and deal with malocclusion, inadequate cosmetics,

periodontal problems, and other structural, functional and aesthetic issues. They then must play analyst and psychologist, helping people with psychogenic issues that have blocked their care over time. Lastly, they facilitate financial discussions and help people to value the investment they are being asked to consider. This is a complex job description but it can be simplified when patients are ready and willing to accept the proposed care.

By striving to educate our patients as to their complete options, we educate them as to the dynamic nature of dentistry. Denture fabrication can result in a patient leaving a practice for years at a time. In our denture brochures, the first thing I have written after denture care instructions is “What’s next?” A significant responsibility for dentists is to discuss the sequelae of prolonged denture wear, the resultant bone loss, digestive problems, and other health issues caused from a breakdown of their chewing efficiency caused by osseous deterioration.

### Should we Consider Mini-Implants?

For patients who require improved retention and are dealing with lower budget limits, mini-implant supported dentures are an upgradeable option over Turbyfill Deluxe dentures. In figure 3a we see a patient promptly after receiving an immediate maxillary complete denture. She was unable to eat, speak or swallow and was therefore emotionally distraught over her inability to tolerate palatal acrylic coverage. After careful planning, 12 Imtec mini-implants were placed (Figs. 3b and 3c). The metal reinforced partial dentures (Figs. 3d and 3e), which have been in place now for 2 years, achieved aesthetics, phonetics and function. Both overdentures were reinforced with a metal frame to provide strength. They

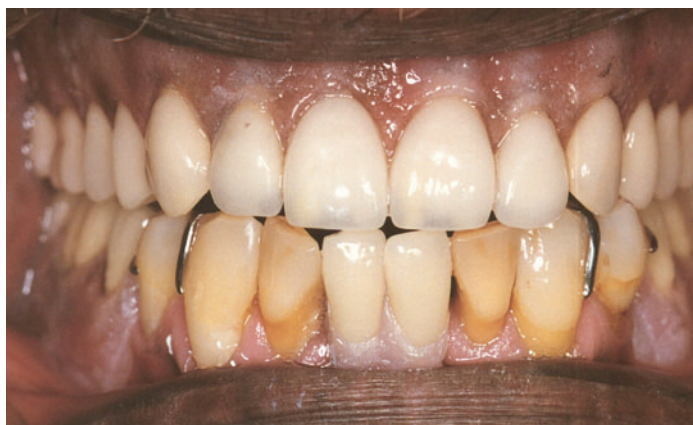

Fig. 1: Turbyfill Deluxe maxillary complete denture and mandibular partial denture with a soft liner (Molloplast, Buffalo), ethnic tinting, and Ivoclar Processing.

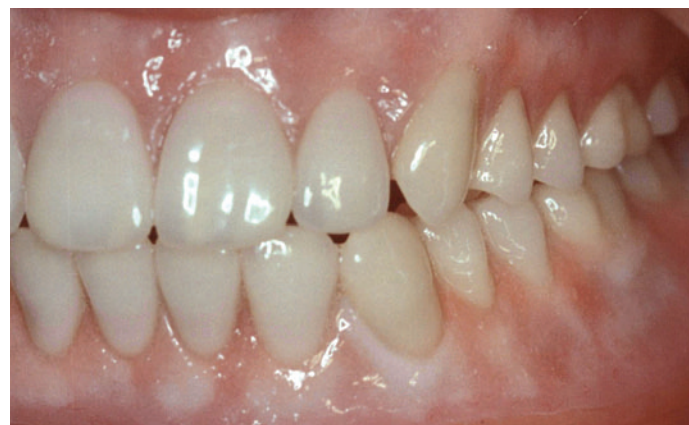

Fig. 2: Upper and lower Turbyfill Dentures with white tinting. The lower denture has a soft lining.



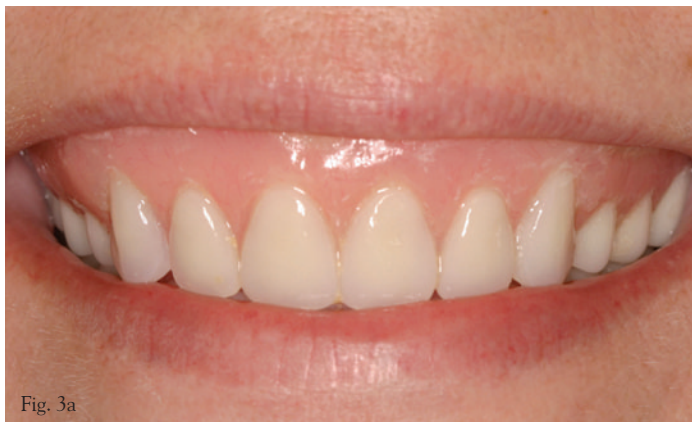

Fig. 3a

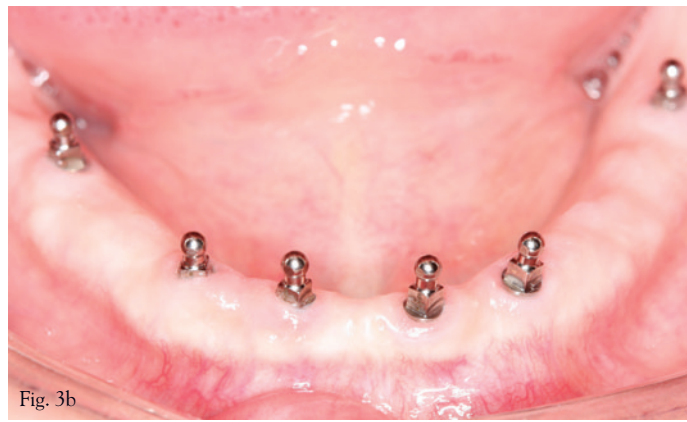

Fig. 3b

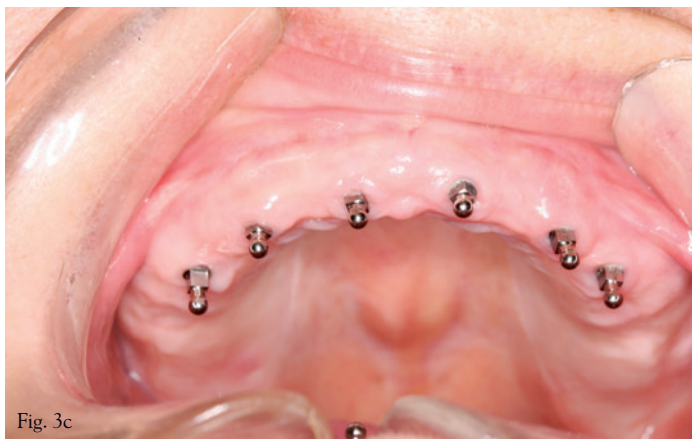

Fig. 3c

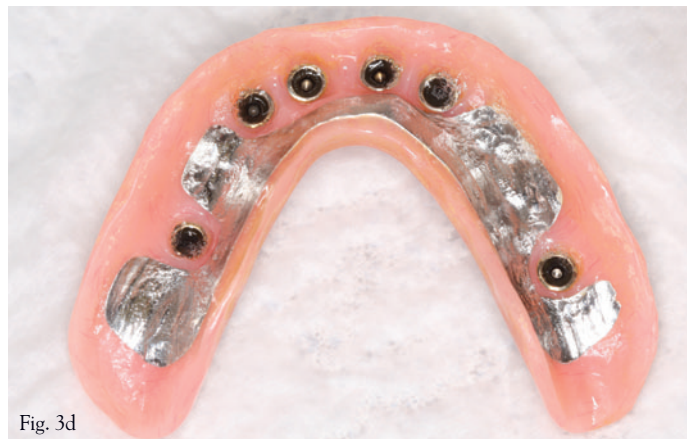

Fig. 3d

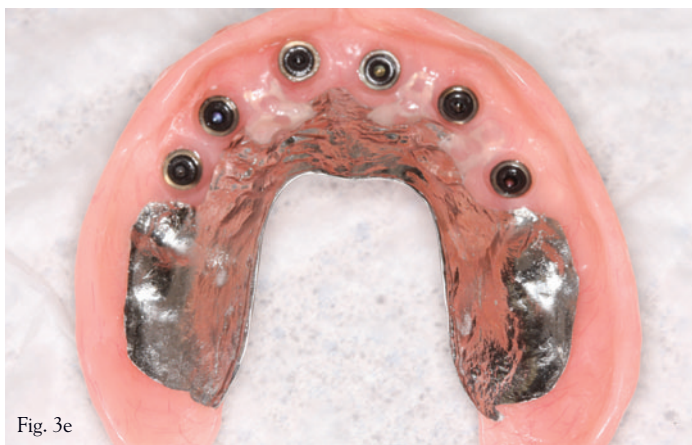

Fig. 3e

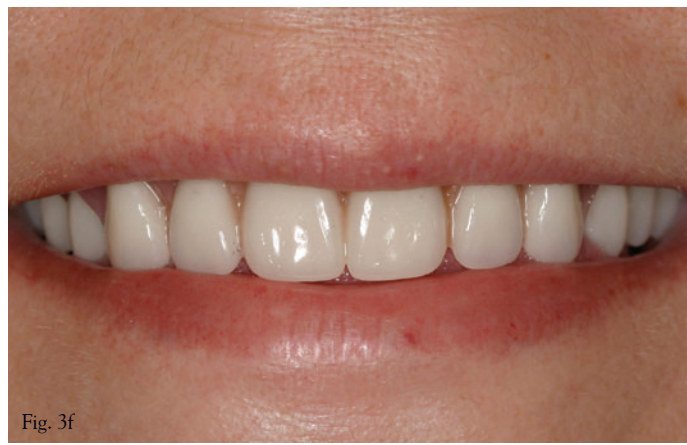

Fig. 3f

Fig. 3a: Preoperative appearance of patient who presented with immediate dentures that were intolerable.

Fig. 3b: Six mandibular mini-implants were placed.

Fig. 3c: Six maxillary mini-implants were placed.

Fig. 3d: Mandibular metal reinforced mini-implant overdenture.

Fig. 3e: Maxillary metal reinforced mini-implant overdenture.

Fig. 3f: Full smile after delivery of the implant retained overdentures.



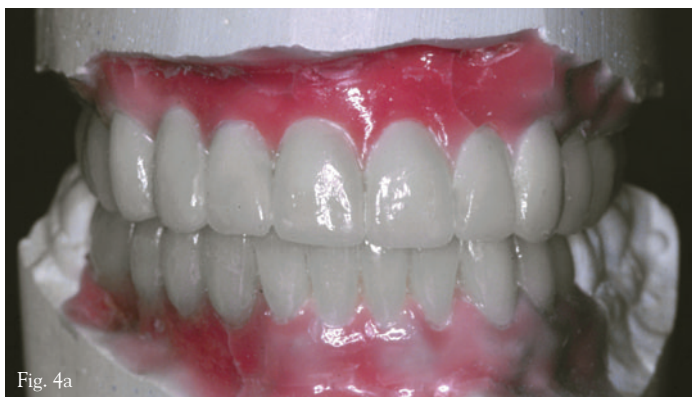

Fig. 4a

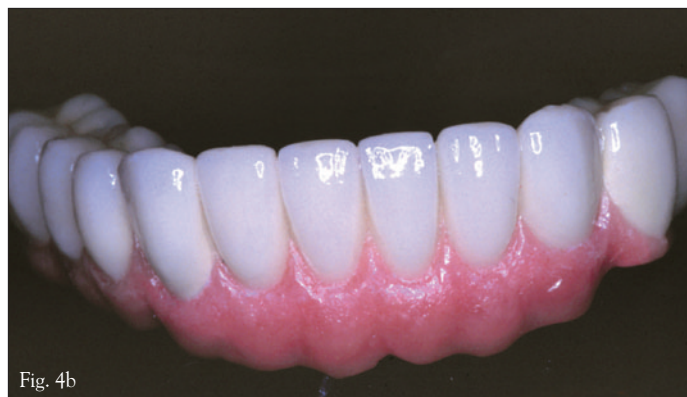

Fig. 4b

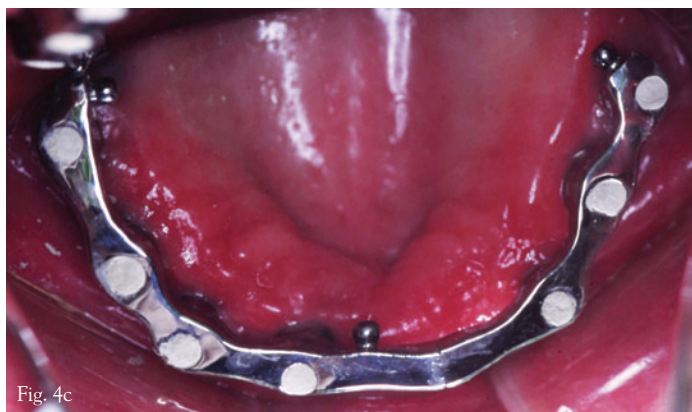

Fig. 4c

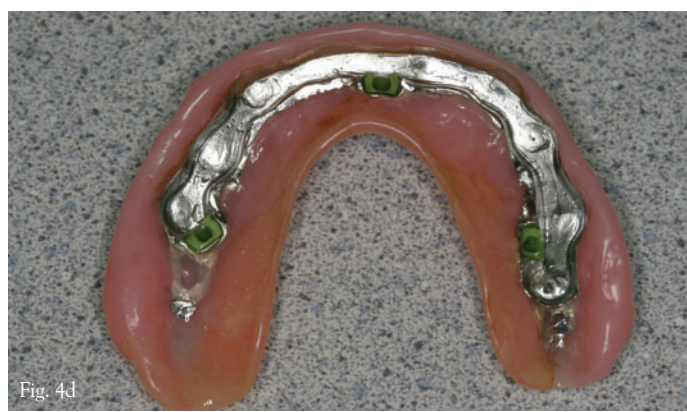

Fig. 4d

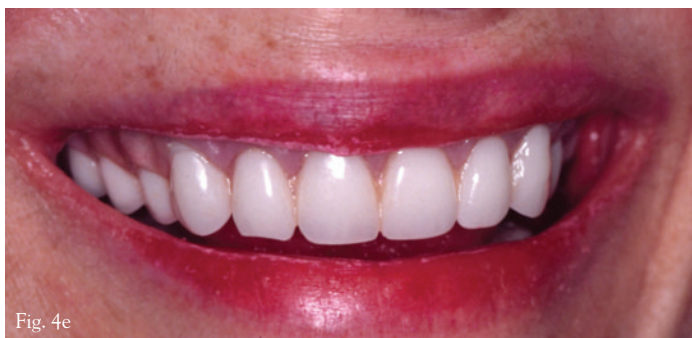

Fig. 4e

Fig. 4a: Master diagnostic models were prepared by the laboratory.  
 Fig. 4b: A Porcelain-fused-to-gold bridge was used for mandibular reconstruction  
 Fig. 4c: Maxillary bar on 8 BioHorizons implants with Bredent attachments. Bar is connected with a male-female interlock.  
 Fig. 4d: Maxillary overdenture for bar showing the metal housing in the overdenture, the milled metal, and Bredent attachments.  
 Fig. 4e: Smile after delivery of the bar-retained overdenture.

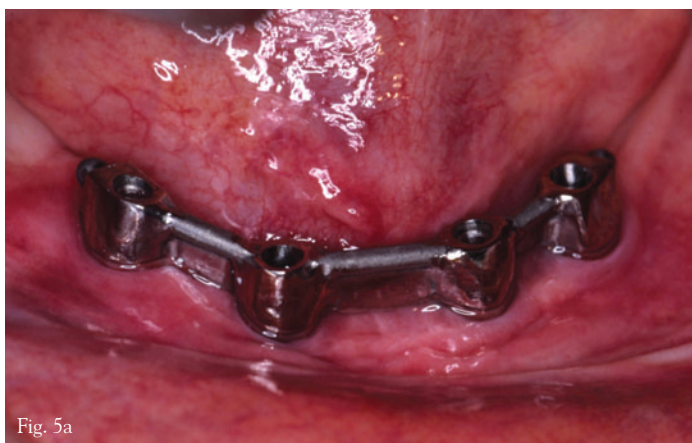

Fig. 5a

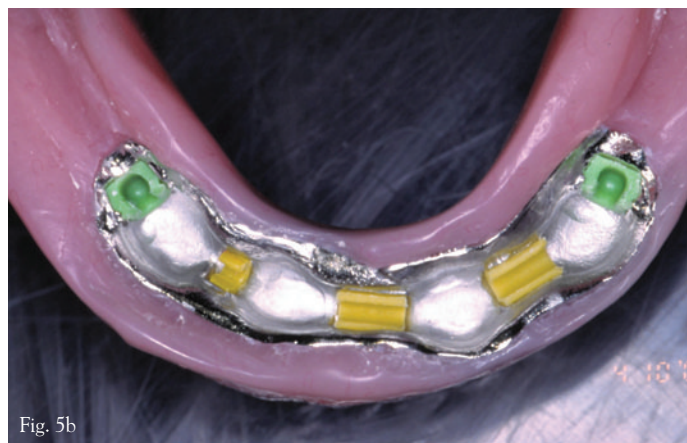

Fig. 5b

Figs. 5a: Mandibular bar using 4 implants for an overdenture .

Figs. 5b: Metal reinforced overdenture showing Bredent attachments, Hader Clips and a milled metal substructure.



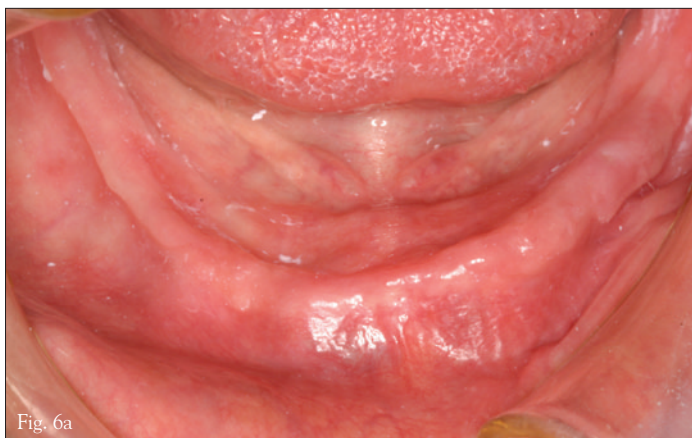

Fig. 6a

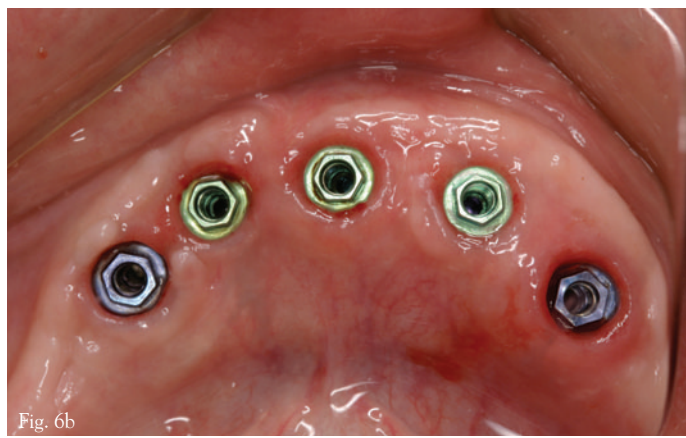


Fig. 6b

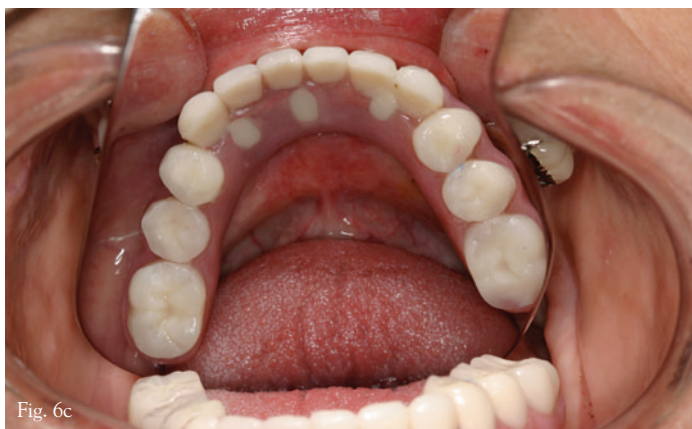

Fig. 6c

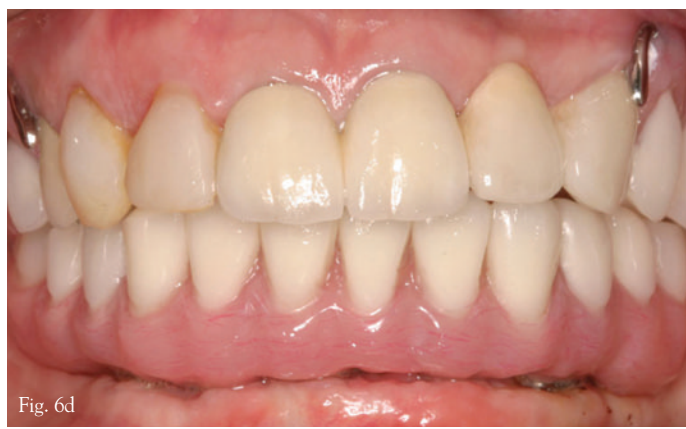

Fig. 6d

Fig. 6a: Patient with an atrophic mandibular ridge. (Deficient in height and width).

Fig. 6b: Patient after onlay grafting and placement of 5 implants in ABCDE positions.

Fig. 6c: Hybrid prosthesis with access holes covered.

Fig. 6d: Retracted view of hybrid with maxillary dentition in lingualized occlusion.

were designed with an acrylic window around the “keeper caps” so the metal frame will remain intact should replacement or a reline become necessary at a later time. The patient reported that she has no desire to upgrade, she able to eat and enjoy any food, and was pleased with the aesthetics (Fig. 3f). While these mini-implants may not be as “ideal” as “traditional” implants, they will preserve bone and options for an upgrade path.<sup>6</sup>

### Removable and Fixed Partial Dentures: The Reality

Do we teach patients about bone sparing dentistry? According to Misch<sup>7</sup>, removable partial denture survival is 60% at 4 years, and there is a repair rate of abutment teeth of 80% at 10 years with accelerated bone loss secondary to partial denture wear in edentulous areas. He goes on to say that half the patients wearing a partial denture chew better without the device. Only 60% of people with a lower free-end saddle partial are still

wearing them after 4 years.<sup>8, 9</sup> A study by Aquilino<sup>9</sup> reported a 44% abutment tooth loss within 10 years when wearing removable partials. Do we tell this to our patients?

A failing 3-unit fixed partial denture (bridge or FDP) can be upgraded to an implant and 2 crowns to allow for easier flossing, less bone loss in the missing tooth area, and less chance of decay around the retainers. The literature has discussed failure rates for FPD from 74% at 15 years as reported by Creugers, to 20% loss over 3 years according to Bloom et.al.<sup>10</sup>, Schwartz, et. al.<sup>11</sup> and Misch<sup>7</sup>. Approximately 8% to 12% of FPD teeth are lost within 10 years as a result of endodontic failure or fracture.<sup>7</sup>

Removable partial dentures that have unsightly clasps that lead to decay and loosening of the clasped teeth can be upgraded to implant bridges or implant retained “over partials”. These alternatives will preserve bone and not allow as much food to get stuck under the prosthesis. They

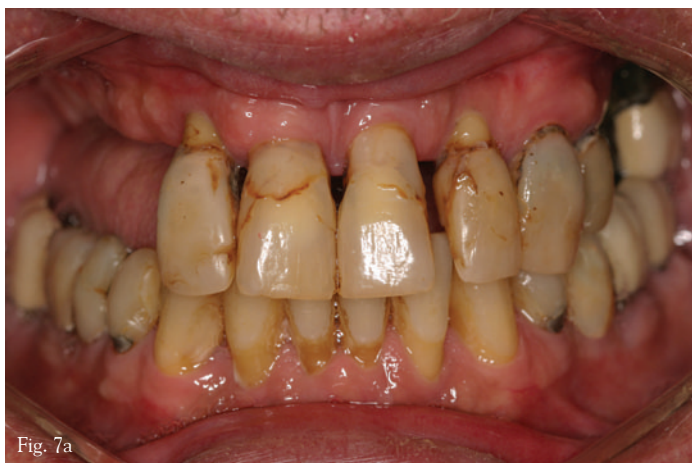

Fig. 7a

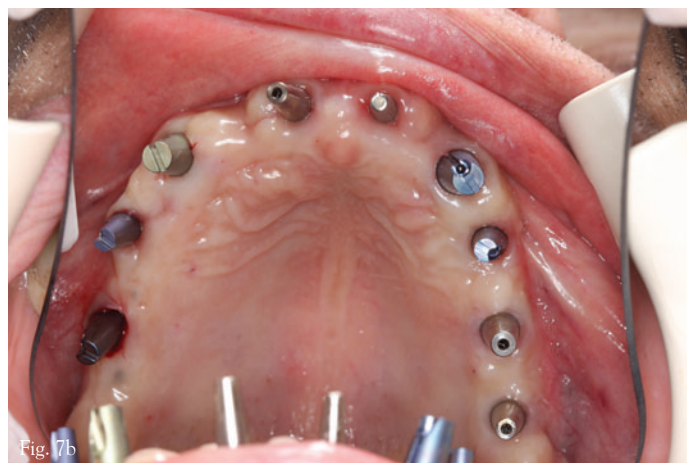

Fig. 7b

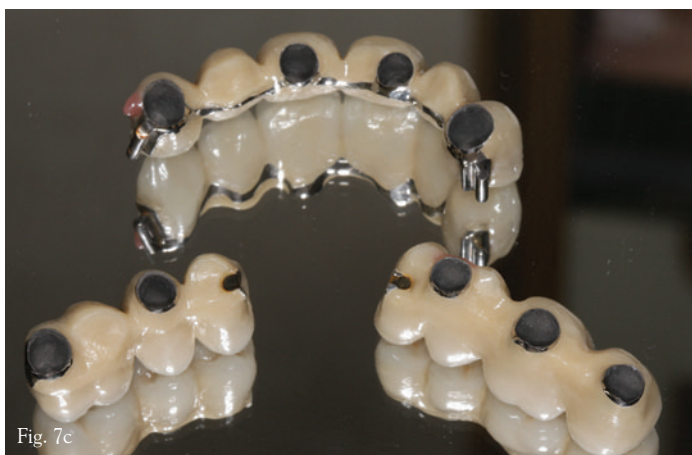

Fig. 7c

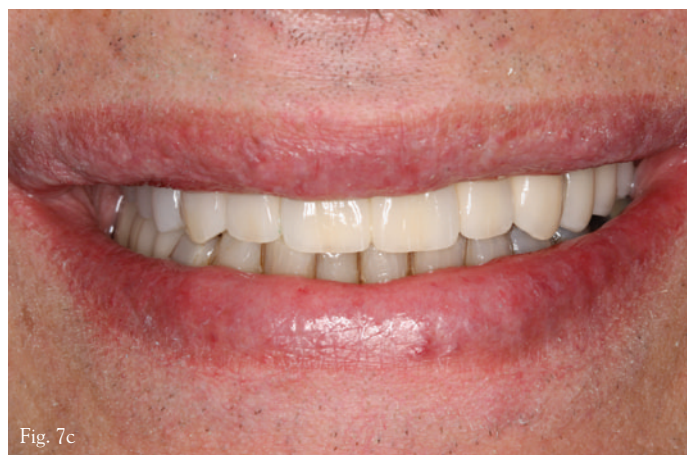

Fig. 7d

Fig. 7a: Periodontally hopeless dentition for full-mouth implant rehabilitation.  
 Fig. 7b: Nine Tatum implants with abutment for fixed bridgework.  
 Fig. 7c: Fixed bridgework in 3 sections. Rigid connectors distal to canines.  
 Fig. 7d: Full smile after cementation of final implant bridges.

will also give patients better chewing forces, improved stability and a more evenly distributed biting scheme to preserve any remaining teeth. Implants decrease tipping of partials and dentures or greatly diminish it while adding retentive elements. The nature of a removable prosthesis is that it is removable (or moveable) which can lead to, as I describe it to my patients, biting on a “diving board” of teeth. This is another way of describing a free-end saddle partial denture. This may cause fractures, loosening of teeth, bone loss, mobility, pain, or sensitivity to the teeth adjacent to the “diving board”. The idea of placing an implant(s) or a series of mini-implants to stop the rotations, tipping and lateral movements or the simple act of holding it in without a denture crème is reason for our patients to celebrate.

### Bar Overdentures or Hybrids? Case Examples

The photos in figure 4 deal with a patient who had been presented with an extensive treatment plan for rehabilitation in another office. The proposed dental treatment was to include laser-assisted ENAP and fixed restorations at a cost of \$40,000. After thorough examination in our office, we found her teeth to be non-restorable due to poor crown-to-root ratios and mobility. Our treatment plan for her was to place 8 maxillary with an implant-supported bar and overdenture, as well as a mandibular fixed bridge (FP-3). Figure 4a shows master diagnostic model (MDM) and figure 4b shows the porcelain-fused-to-gold bridge for her mandibular reconstruction. Figure 4c shows the 2-piece bar on 8 maxillary implants retaining the maxillary overdenture. A



maxillary bar with a milled superstructure has allowed for an RP-4 prosthesis, which provides for a stable implant based occlusion. Figure 4d shows the intaglio of the metal reinforced maxillary overdenture and Figure 4e shows the completed smile. This patient has severe osteoarthritis and has now been functioning pain-free for 6 years.

While there is literature to support splinting of implants to achieve cross-arch stabilization and support, the uses of bars or hybrid dentures are both ways of accomplishing this task. The decision to create a removable prosthesis versus a fixed restoration involves factors related to cost, oral hygiene, available space, smile display, and patient desires. In figure 5a, a bar-supported overdenture was fabricated with 4 implants. The metal reinforced intaglio of the overdenture housed 3 Hader clips and 2 Bredent attachments, as seen in figure 5b.

The ultimate goal of upgradeable dentistry is to give people the ability and the dignity to choose better dental options as they can afford them. The denture is not a destination but a temporary solution to lack of teeth. This temporary fix can be used until dentures retained with implants via balls/bars or implant dentures can be afforded. The last option, that is fully implant borne, would be full-arch rehabilitation with porcelain-fused-to-gold bridges.

### **In fact one can easily envision the following scenario:**

A patient comes in with an ill-fitting upper denture and a few mobile lower teeth that hurt. They can't afford to do too much, but have a yearly budget for their dental care. This person could start with a nice set of provisional dentures and then progress to nicer dentures with soft liners and tinted gums (Ivoclar processing and customized denture tooth set up, Turbyfill dentures) in 1 or 2 years (Figs.1, 2). They could have standard dentures and invest in two or more mandibular implants. The dentist could retrofit the lower denture to hold on to the implants and the person would have dignity of increased retention for their lower denture. If the patient is satisfied, they can stop for the time being while being educated about bone loss in nonimplanted areas of bone. They could be taught about "combination syndrome"(where implants in one arch could accelerate bone loss in the opposing arch due to increased biting forces) and come up with a future plan for treating that arch.

The patient could have additional implants and the dentist could fabricate a bar that is specially milled with attachments to allow the entire denture to sit on the bar or on the bar and soft tissue, an RP-5 or RP-4 prosthesis according to the nomenclature set forth by Dr. Carl Misch.

At this point, the implants are preserving bone and the metal-reinforced denture is stronger than what they had previously. In addition the proprioception (or chewing perception) is much greater as the prostheses are now "connected" to the brain through the bone/implants.

In figure 6a we witness the sequelae of long-term denture wear. The bone loss is evident and the placement of 5 (Fig. 6b) required grafting. Figure 6c shows the seated hybrid restoration, and figure 6b shows the aesthetic relationship of the lower prosthesis with regard to the maxillary dentition. It is of note that this patient had been previously treatment planned for a \$20,000 maxillary restoration with a new lower denture. We offered her a choice to invest her money with a much different emphasis.

With appropriate numbers of maxillary implants, palatal acrylic can be removed so a person can taste their food better; chew more solidly, feel temperatures and live a more comfortable chewing existence. If the person chooses to progress further, they can have the bars removed and have a few more implants placed. This allows for the placement of hybrid prostheses or porcelain-fused-to-gold bridges thereby completing the restoration of a macerated dentition. Now, they have almost the same bridges as someone who just lost a few teeth and can contemplate whether they want a partial, a bridge or implants. The cycle is approaching completion. We have rehabilitated a person with severe dental disability back into a traditional dentate person.

### **Treatment Acceptance: A Shared Responsibility**

The ability of a patient to accept dental care is most often limited by the mind of the dentist presenting a treatment care plan! This is what I believe with all my heart. We need to educate our patients about the dynamic process of dentistry. The ability to upgrade our dentistry to the betterment of our patients' comfort and aesthetic demands will lead to more professional satisfaction as well as a renewed respect and admiration from our patients.

"The Seven Habits of Highly Effective People" by Stephen Covey teaches us to "begin with the end in mind" and "put first things first". The truth has never been more evident than it is in dentistry. The end point of dentistry can be a white filling, a gorgeous set of composite or porcelain veneers, mini-implant supported overdentures, bar retained overdentures or implant supported bridges. The reason that your patient doesn't have these things may be because you did not begin with the end in mind. We need to teach our patients that the process of dentistry is evolving, not static. We can start with treatment partials, and it will be marvelous



treatment if that is all they can afford. The next step(s) are up to you.


Figure 7a demonstrates a severe AAPIV periodontally hopeless dentition with the placement of 9 Tatum implants (Fig.7b). The three piece porcelain-to-gold bridges were made with stress breakers distal to the canines (Fig. 7c). The final prosthesis (Fig. 7d) was the culmination of coming full circle from edentulism to becoming fully "dentate". Upgradeable dentistry is a pathway to patient satisfaction, health and prosperity.

This article series is not meant to be an exhaustive treatise on the methodology or philosophy in treating these cases. It is meant as an overview of the plethora of treatment options available and the ability of patients to say "Yes!" as long as we are flexible with our treatment options and sequencing.

#### Reference:

1. Homoly, Paul. Making It Easy for Patients to Say "Yes". 1st. Charlotte: Homoly Communications Institute, 2001.
2. Contemporary Implant Dentistry Third Edition, Mosby Dr. Carl Misch 2008, p-16-18
3. Koivumaa KK, Hedegard B, Carlsson GE: Studies in partial denture prostheses: I. An Investigation of dentogingivally supported partial dentures, Suom Hammaslaak Toim 56:248-306, 1960
4. Carlsson G.E., Hedegard B, Koivumaa KK: Studies in partial denture prosthesis: IV. A 4-year longitudinal investigation of dentogingivally-supported partial dentures, Aetu Odontol Scand 23:443-472, 1965
5. Aquilino SA, Shugars DA Bader JDet. Al: Ten-year survival rates of teeth adjacent to treated and untreated posterior bounded edentulous spaces, J Prosthet Dent. 85:455-60, 2001
6. see 1, pp 1-25
7. Bloom B, Gaft HC Jack SS: National Center for Health Statistics. Dental Services and Oral Health. U.S., 1989 Vital Health Stat 10 (183), DHHS Pt No (PAS)93-1511 Washinton, DC, 1992, US Gov't. Printing Office
8. Schwartz NL, Whitsett, Berry TG: Unserviceable Crowns and Fixed Partial Dentures: life-span and causes for loss of serviceability, J. Am. Dent Assoc.81:1395-1401, 1970.
9. See 1, Misch pp. 6-20.
10. Mancuso, DN,Goiato MC, Gennari, FilhoH, Gomes,EA. "Bite force and masticatory efficiency in implant-retained dentures: literature review.." Dent Today 8(2008): 56-58.
11. Shigli, k,Shivappa,Angadi G, Gegde P, Hebbal, M. "Patients' knowledge and understanding of the implications of wearing dentures. Report of a survey conducted at a dental institute in the south of India." Prim Dent Care 15(2008): 85-89.
12. LaBarre, EE, Ahlstrom,RH, Noble, WH. "Narrow diameter implants for mandibular denture retention.." J Calif Dent Assoc 36(2008): 283-6.
13. Siadat, H, Alikhasi, M, Mirfazaelian, A,/ GermanipناهH, Geramipناه, F,Zaery,F."Patient satisfaction with implant-retained mandibular overdentures: a retrospective study.." Clin Implant Dent Relat Res. 10(2008): 93-8.
14. Turbyfill, WF. "Impression techniques for removable partial dentures." Gen Dent 49(2001): 358-64.
15. Turbyfill, WF. "The successful mandibular implant denture--part one." Dent Econ 85(1995): 70-1.
16. Turbyfill, WF. "Excellence in complete dentures." Dent Econ 84(1994): 80-1.
17. Turbyfill, WF. "Regaining pleasure and success with complete denture services." Int J Prosthodon 5(1989): 474-82.
18. Cavallaro, Js Jr, Tarnow, DP. "Unsplinted implants retaining maxillary overdentures with partial palatal coverage: report of 5 consecutive cases." Int J Oral Maxillofac Implants 5(2007): 808-14.
19. Shatkin, TE,Shatkin,S,Oppenheimer,BD,Oppenheimer,AJ. "Mini dental implants for long-term fixed and removable prosthetics: a retrospective analysis of 2514 implants placed over a five-year period." Compend Contin Educ Dent 28(2007): 92-9.

Reprinted by permission of Dentistry Today, c2009 Dentistry Today.



# INCISAL EDGE DENTAL LABORATORY

*Cosmetics Without Compromise*

Certified laboratory for CAPTEK, CRISTOBAL+, IPS EMPRESS, IPS E-MAX, PROCERA, ATTACHMENTS, IMPLANTS, CUSTOM IMPLANT ABUTMENTS & LASER WELDING.

Looking after all of your Dental Laboratory needs.  
We pride ourselves on quality work, great service and exceptional value.

Thomas Kitsos, RDT #92184  
3410 Yonge Street • Toronto, Ontario • M4N 2M9  
Tel: (416) 806-9057 • 1-877-INCISAL • Fax: (416) 489-6541