

Compromised Foundations Require Confident Conversation



Richard Winter,
DDS

INTRODUCTION

As general dentists, we have undergone extensive training in prosthodontic principles and prostheses fabrication. The well-documented sequelae of prolonged denture use include: severe attrition of the residual alveolar bone, pronounced mylohyoid ridges, tongue hypertrophy, and mental nerve dehiscence. These are accompanied by emotional and psychogenic patient dissatisfaction.¹

When patients present with severely atrophic maxillas and mandibles, dentists often evaluate this situation from their own existing perspective, which may not include discussion of subantral sinus augmentation, ramus grafting, symphyseal grafts, sub-periosteal implants, ridge spreading, or hip grafting. Dentists must take a greater role in becoming advocates for their patients on their journey toward patient-specific, customized treatment planning. It is incumbent on the general practitioner to educate patients about options to rebuild their atrophic foundations.

The premise of this article and case report is to demonstrate the need, and perhaps learning curve required, to educate our patients about options to restore the lost restorative interface. In this article, the focus is on additive procedures; the ability to converse with our patients about osseous augmentation will allow them to choose an “upgrade path”² that fits their restorative and financial needs.

CASE REPORT

Diagnosis and Treatment Planning

A patient with severe pain presented with symptoms of denture discomfort and pain upon chewing. This was due to acute irreversible pulpitis and acute apical periodon-

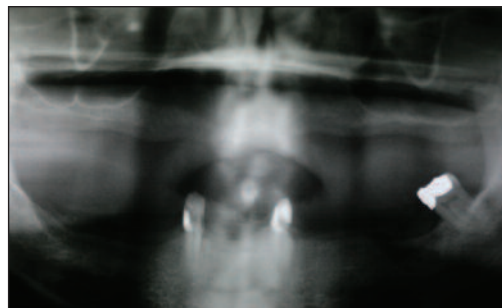




Figure 1. Preoperative panoramic radiograph (Panorex) of severely atrophic maxilla and mandible with only 3 remaining teeth.



Before. Preoperative smile.



After. Postoperative smile.

titis on the lower canines with fremitus of the 3 remaining lower teeth. The options of denture and partial denture replacement had been discussed with 3 previous dentists, but due to the lack of bone present, no implant options had been discussed.

In Figure 1, the panoramic radiograph (Panorex) revealed a C-H ridge and an SA-4 sinus situation; which meant there was less than 5 mm of vertical bone below the maxillary sinus.^{3,4} Figure 2 shows severe mandibular ridge atrophy; a C-H ridge as well. This patient was healthy with a non-contributory health history. His journey was to include bilateral sinus augmentation, bilateral ramus grafts, and a symphysis graft. After this, he would receive maxillary and mandibular implants with Atlantis (Astra Tech) abutments and finally upper and lower implant-supported hybrid prostheses. While the process of upgradeable dentistry¹ had been discussed as a sequential rehabilitation as one of his options, he chose to complete his entire rehabilitation from the onset of treatment.

Clinical Treatment

The surgical visits were all performed by a general practitioner (Dr. John Werwie), which has the advantages of allowing us to speak the same language with regard to prosthodontic principles and prosthesis generated implant placement. Figure 3 demonstrates the maxilla exposure prior to

bilateral subantral sinus augmentation. Full thickness mucoperiosteal flaps were reflected, and a lateral window was created to allow for elevation of the Schneiderian membrane with sinus curettes (Figures 4 and 5). The elevation of the membrane allowed the surgeon to place an antibiotic impregnated membrane and a mixture of demineralized and mineralized bone allograft (Grafton and MinerOss [BioHorizons]) mixed with plasma rich protein (PRP) (Figure 6). The inferior layer of the graft was autogenous bone, which was placed after achieving some scoring of the sinus floor to accomplish a regional acceleratory phenomenon (RAP) thus promoting angiogenesis to the area. AlloDerm (LifeCell [a KCI Company]), tacked to place prior to block grafting in the anterior maxilla, was used to cover the window (Figure 7). The use of autogenous bone is the gold standard in block grafting, and the ramus graft (Figure 8) as well as the symphysis graft (Figure 9) allowed for the proper size implants to be used to support full-arch restoration.⁵ The harvested graft was then held while screw access holes were prepared to facilitate fixation to the host site (Figure 10). Then, the blocks were stabilized by forming a mortise inferior to the block, to decrease the incidence of block micromovement and soft-tissue invagination between the block and host bone. The host sites were also decorti-

continued on page xx

Compromised Foundations...

continued from page 00

cated with many holes perforating the cortex to create blood flow to the block and create the RAP effect.

The autogenous bone and allograft were bathed in PRP (Figure 11) to further impregnate the bone with growth factors designed to assist in accelerating integration and soft-tissue healing. As seen in Figures 12 and 13, the bone was placed in the key implant locations.⁶ The treatment plan called for the placement of implants in terminal abutment positions, first molar, and canine areas. While anterior implants were desirable, the quality of bone post grafting was insufficient to allow for an anterior implant. At the time of surgery, the surgeon and restorative dentist made the decision to utilize the 8 maxillary implants; and due to cross-arch stabilization, implant diameter, and A-P spread, further grafting was deemed unnecessary in this instance for placement of an anterior implant. Figures 14 and 15 show the blocks after 6 months of integration prior to screw removal and implant placement.

Some of the mineralized bone allograft was apparent around the graft. The panoramic radiograph demonstrated the fixation screws and lack of radiolucency around the grafted segments (Figure 16). The fixation screws were removed and the implants placed (Figure 17). Block grafting with autogenous bone is a predictable modality for treatment of severe atrophy with success rates of the graft that can approach 97%.⁷ Long-term denture use and its concomitant alveolar atrophy required foundation augmentation with autogenous bone. The use of endosseous implants placed in a timely fashion within the newly grafted bone will provide osseous stimulation that will lead to long-term graft retention and implant longevity.^{8,9} While block grafting is a predictable modality, there will be resorption of the block, and failure to place implants within one year may result in the need to re-graft the area prior to implant placement. The surgical guide was fabricated in the restorative dentist's office by making a Lang Duplicate of the approved denture and cutting out the facial of the anticipated implant sites. The osteotomy was initiated and the 1.8 mm guide pin was used to check angulation in the buccal/lingual as well as mesial/distal orientation (Figure 18). The areas in the Nos. 8 and 9 positions (Figure 18) on the surgical

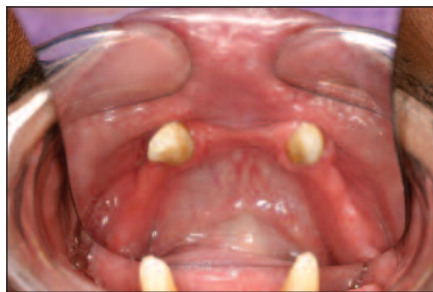

Figure 2. Occlusal view of atrophic mandible.

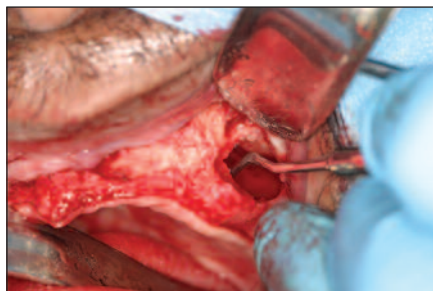


Figure 5. Elevation of Schneiderian membrane, in preparation for augmentation.

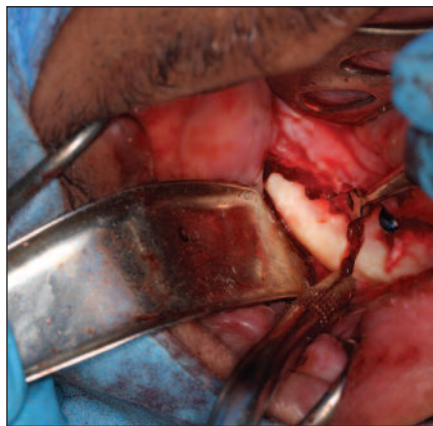

Figure 8. Exposed ramus in preparation for harvesting.

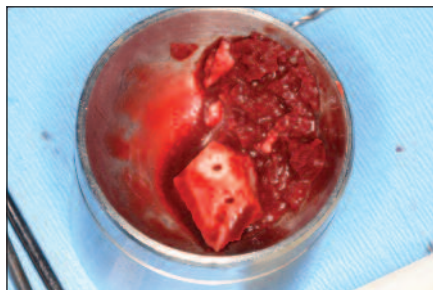


Figure 11. Block graft, plasma rich proteins, and bone grafting materials prior to placement.

guide were removed prior to surgery. Again, remember that the ability to interact with the surgeon during complex surgical procedures is a valuable adjunct to restorative success.

The panoramic radiograph (Figure 19) as well as the occlusal view of the implants after uncovering and removal of per mucosal extensions (Figure 20) demonstrates the nice alignment, parallelism, and facilitation of the cementable hybrid prosthesis. A Duralay jig was used to veri-

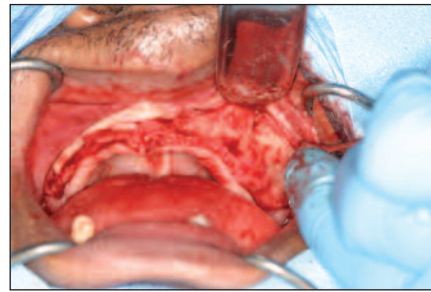


Figure 3. Maxillary arch exposed for bilateral subantral sinus augmentation and symphysis block grafting.

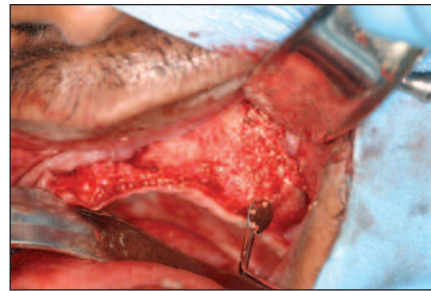


Figure 6. Grafting material placed into subantral space. Demineralized and mineralized allograft and autogenous bone (Grafton and MinerOss BioHorizons) mixed with plasma rich protein was placed prior to sealing the grafted area.

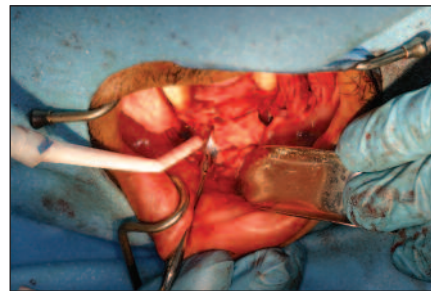
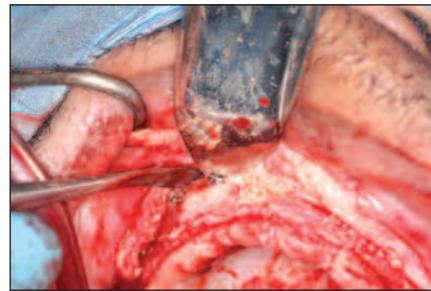


Figure 9. Elevation of block of bone from the symphysis.

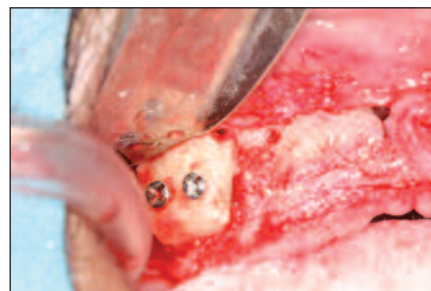

Figure 12. Fixation of the graft with 2 titanium fixation screws.



Figures 14 and 15. Block grafts after 6 months of healing and prior to screw removal and implant placement.

fy accuracy of the full-arch impression (Figure 21) taken using light/heavy vinyl polysiloxane materials (Aquasil Ultra Smart Wetting [DENTSPLY Caulk]).

Drs. Harold Shavell and Walter

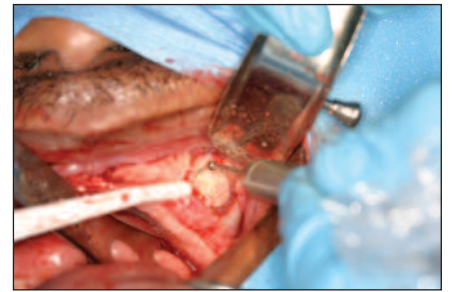

Figure 4. Lateral window outlined for sinus membrane elevation.

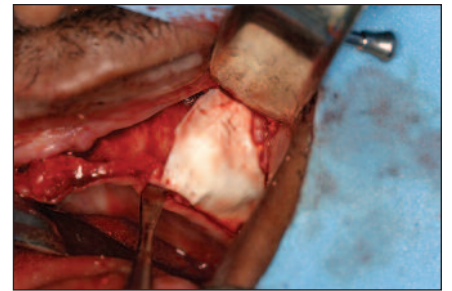


Figure 7. AlloDerm (LifeCell [a KCI Company]) was used to seal lateral window with tacks to prevent migration of the graft.

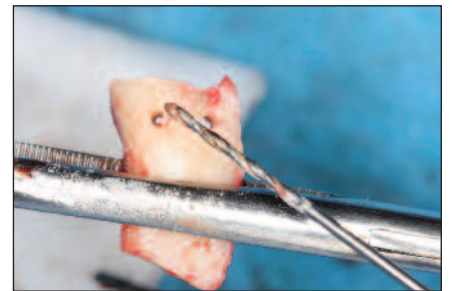

Figure 10. Perforation of the block graft prior to stabilization at the recipient site.

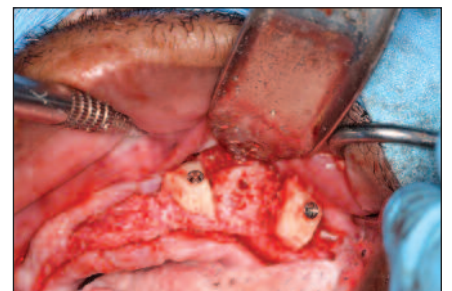
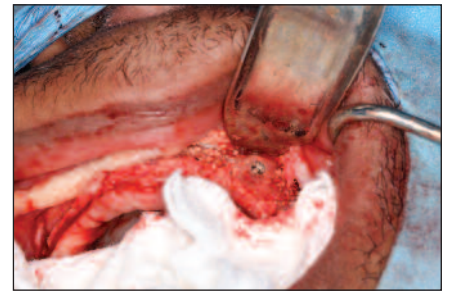


Figure 13. Monocortical blocks placed at sites of future implant sites.



Figures 14 and 15. Block grafts after 6 months of healing and prior to screw removal and implant placement.

Turbyfill teach the use of provisionalization to test and verify success from a functional and aesthetic perspective before constructing the definitive prosthesis. The use of provisionals for

continued on page xx

Compromised Foundations...

continued from page 00

fixed crowns and bridges and the branching techniques for denture success are tools these clinicians used for years to verify occlusal vertical dimension, comfort, and function, utilizing a prototype restoration as a “blueprint for success.” These pioneers of dentistry taught that form follows function and that form and function are one. As my good friend and mentor Dr. Ara Nazarian says in his lectures, “The eyes don’t lie” (Figure 22).

The final prosthesis demonstrated the laboratory team’s excellent attention to detail with regard to melanin pigmentation as well as replicating the finalized occlusion that was worked out in the interim denture (Figure 22, Before Image, and After Image).

DISCUSSION

Our patient completed a video testimonial of his journey (available for review at dentistrytoday.com). It was not until after completion of his full-mouth rehabilitation that he had revealed the depth of his depression. He had reached such a level of despair that he felt trapped and unable to cope with everyday life. While this was not ever apparent to me during the patient interview or even during subsequent appointments, this patient presented all the details of his journey after successfully completing his restoration. The patient’s psychological outlook has changed dramatically. He has lost weight due to vigorous exercise, and enjoyed a better diet and an improved feeling of well-being. He explained his decision to undergo the treatment as being the result of finding a dentist who would *listen* to him and present *solutions* that would solve his severe problems. He further appreciated the fact that I, as his restorative dentist, promised to accompany him to his surgical appointments.

The initial relationship with the restorative dentist can be a powerful motivator in completing comprehensive treatment. The presence of the restorative dentist at the surgery will allow for interaction with the surgeon, so that any problems or compromises could be discussed to mitigate any potentially negative sequelae due to unforeseen surgical situations. While many dentists could not take that time away from the office, I see it as an invaluable way to increase my knowledge of these complex surgeries as well as learning firsthand of the surgical

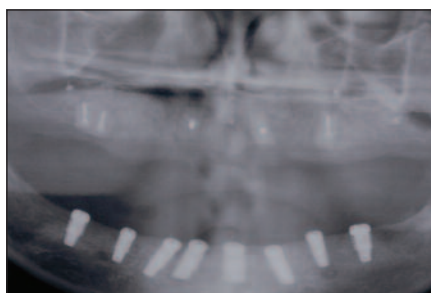


Figure 16. Panoramic radiograph showing the fixation screws for all of the block grafts placed. The mandibular 8 implants (BioHorizons) had been placed already.

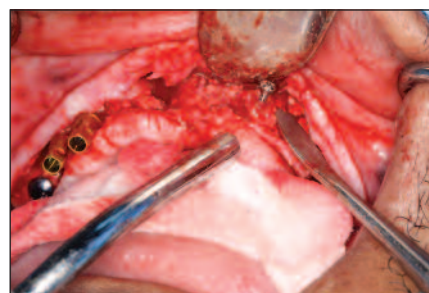


Figure 17. Removal of the fixation screw with concomitant placement of the maxillary implants.

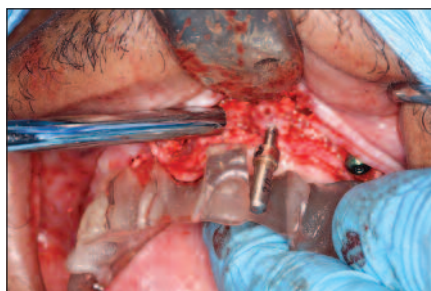


Figure 18. Surgical guide utilized to guide implant placement in 3 planes.

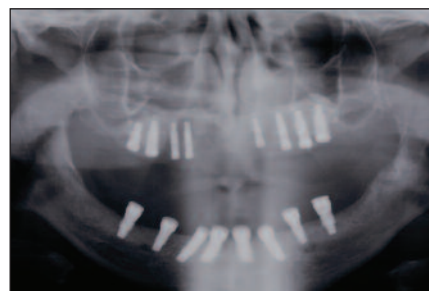


Figure 19. Panoramic radiograph with maxillary and mandibular implants in place.

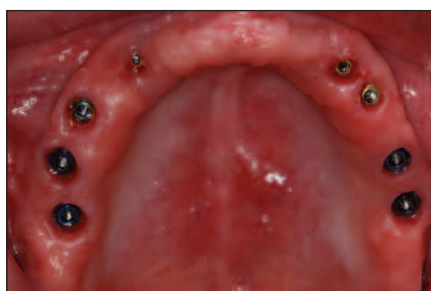

Figure 20. After uncovering of the permucosal extensions, prior to abutment placement.

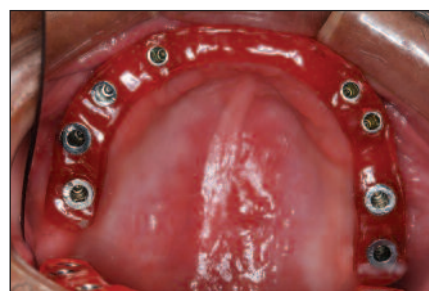

Figure 21. A DuraLay (Reliance) jig was used to verify accuracy of the impression. The seating of the abutments (Atlantis [Astra Tech]) was verified directly prior to seating the hybrid prostheses.

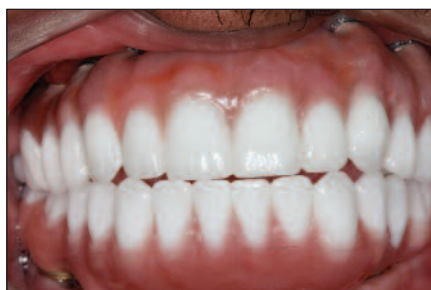

Figure 22. Completed full-mouth rehabilitation with maxillary and mandibular hybrid prostheses after bilateral sinus augmentation and symphyseal and ramus grafting.

complications, postoperative sequelae, and experiences the patient is undergoing during his or her “journey.” These opportunities for photographing and documenting cases allow me to better educate future patients about their situations. This may be a path that we can all benefit from in order to become more literate and verbal with our patients in helping them to rebuild their lost foundations. It is of note that foundations can refer to bone structures as well as “trust” issues. It is a matter of discussion as to which holds more value in the long-term success of our patient treatment.

Patients deserve to be educated and given a wide range of options that

are “dynamic,” according to their emotional, financial and personal needs. If you have never seen one of these surgeries, I encourage you to speak with your surgical implant-placing dentist, whether it is an oral surgeon, periodontist, or general dentist and ask him or her to allow you to observe these procedures. The more familiar you are with the surgeries, the better equipped you will be to discuss this aspect of your patients’ care. “Foundations of success are dependent on our successful foundations” (Lectures on Upgradeable Dentistry by Dr. Richard Winter). This means that if we have a rich foundational understanding of the surgical and prosthetic options available for our patients, even if we choose not to participate in this level of care, we should be conversant and knowledgeable about these options in educating our patients. Prosthodontic success will facilitate our patients’ quest for eating peanuts and lettuce once again! We all know that denture patients have these 2 requests. (They also lost that denture tooth on a piece of soft white

bread, but that is for another article.) Our knowledge base and ability to converse in language they can understand will allow our patients to be flexible and dynamic in selecting their appropriate level of care.

CONCLUSION

The loss of bone as a result of tooth loss, disuse atrophy, and attrition can result in physiological and psychological atrophy. This case study serves as a reminder of how conventional treatment planning can lead to deep depression and emotional distress.

For the patient in this case, not only were his osseous foundations rebuilt; it could be argued that the foundation of his life were positively altered and augmented as well.

As a profession, the challenge that is before us is to not take the treatment-planning path of comfort, simplicity, and insurance limits; rather, it is to facilitate our patients’ journey toward optimal dental health. Whether this entails treatment plans of considerable complexity and expense, or whether we must perform a sequential “upgrade” path for our patients our responsibility remains unchanged. If we give our patients hope, we can often empower them to say yes to treatment planning that is quite complex, and along the path to regenerating lost bone, we can also rebuild lost self-esteem. ♦

Acknowledgement

I would like to thank Dr. John Werwie for his mentorship and friendship on numerous difficult and demanding surgical cases, one of which was outlined in this article. Clinical success wouldn’t be achievable without the dedication to excellence that a professional of this magnitude exemplifies. There was excellent lab support by Burbank Dental Lab’s chief technician, Vincent Nalbandian.

References

- Cooper LF. The current and future treatment of edentulism. *J Prosthodont.* 2009;18:116-122
- Winter RB. Upgradeable dentistry: Part 1. *Dent Today.* 2009;28:82-87.
- Misch CE. Maxillary sinus anatomy, pathology and graft surgery. In: Misch CE. *Contemporary Implant Dentistry.* 3rd ed. St. Louis, MO: Mosby; 2008:914-915.
- Misch CE. Bone density: a key determinant for treatment planning. In: Misch CE. *Contemporary Implant Dentistry.* 3rd ed. St. Louis, MO: Mosby; 2008:130-137.
- Misch CM. Use of the mandibular ramus as a donor site for onlay bone grafting. *J Oral Implantol.* 2000;26:42-49.
- Misch CE. Treatment plans related to key implant positions and implant number. In: Misch CE. *Contemporary Implant Dentistry.* 3rd ed. St. Louis, MO: Mosby; 2008:147-159.
- Levin L, Nitzan D, Schwartz-Arad D. Success of dental implants placed in intraoral block bone grafts. *J Periodontol.* 2007;78:18-21.

continued on page xx

Compromised Foundations...

continued from page 00

8. Misch CE, Zaki HS, Dietsh F, et al. Osteointegrated implants in a microvascular graft to restore a subtotal mandibulectomy—case report. *Int J Oral Implantol*. 1990;7:25-29.
9. Verhoeven JW, Cune MS, Terlou M, et al. The combined use of endosteal implants and iliac crest onlay grafts in the severely atrophic mandible: a longitudinal study. *Int J Oral Maxillofac Surg*. 1997;26:351-357.

Dr. Winter received his dental degree from the University of Minnesota School of Dentistry in 1988. He received his mastership in the AGD in 2007 and has a Fellowship and mastership (Implant Prosthetic Section) in the International Congress of Oral Implantologists. He has a Fellowship in the Academy of Dentistry International. Dr. Winter lectures on topics from alternatives to edentulism to upgradeable dentistry and also provides hands-on courses with Dr. Ara Nazarian on a wide range of topics. He can be reached at rick@winterdental.com.

Disclaimer: Dr. Winter reports no disclosures.

continued on page xx